

CHEST[®]

Official publication of the American College of Chest Physicians



Interpretation of Plain Chest Roentgenogram

Suhail Raoof, David Feigin, Arthur Sung, Sabiha Raoof, Lavanya Irugulpati and Edward C. Rosenow III

Chest 2012;141;545-558
DOI 10.1378/chest.10-1302

The online version of this article, along with updated information and services can be found online on the World Wide Web at:
<http://chestjournal.chestpubs.org/content/141/2/545.full.html>

Chest is the official journal of the American College of Chest Physicians. It has been published monthly since 1935. Copyright 2012 by the American College of Chest Physicians, 3300 Dundee Road, Northbrook, IL 60062. All rights reserved. No part of this article or PDF may be reproduced or distributed without the prior written permission of the copyright holder.
(<http://chestjournal.chestpubs.org/site/misc/reprints.xhtml>)
ISSN:0012-3692





Interpretation of Plain Chest Roentgenogram

Suhail Raoof, MD, FCCP; David Feigin, MD, FCCP; Arthur Sung, MD; Sabiha Raoof, MD, FCCP; Lavanya Irugulpati, MD; and Edward C. Rosenow III, MD, Master FCCP

Plain chest roentgenogram remains the most commonly ordered screening test for pulmonary disorders. Its lower sensitivity demands greater accuracy in interpretation. This greater accuracy can be achieved by adhering to an optimal and organized approach to interpretation. It is important for clinicians not to misread an abnormal chest radiograph (CXR) as normal. Clinicians can only acquire the confidence in making this determination if they read hundreds of normal CXRs. An individual should follow the same systematic approach to reading CXRs each time. All clinicians must make a concerted effort to read plain CXRs themselves first without reading the radiologist report and then discuss the findings with their radiology colleagues. Looking at the lateral CXR may shed light on 15% of the lung that is hidden from view on the posteroanterior film. Comparing prior films with the recent films is mandatory, when available, to confirm and/or extend differential diagnosis. This article outlines one of the many systematic approaches to interpreting CXRs and highlights the lesions that are commonly missed. A brief description of the limitations of CXR is also included.

CHEST 2012; 141(2):545-558

Abbreviations: AP = anteroposterior; CXR = chest radiograph; PA = posteroanterior

In December 1895, Dr Wilhelm Conrad Roentgen, a German physicist, used cathode rays for medical purposes and produced a fluorescent image of his wife's hand.¹ He coined the term "x-rays" for the then-unknown type of ionizing radiation. For nearly three-quarters of a century, plain chest roentgenograms (CXR) became the cornerstone for diagnosing many lung disorders. It was not until the mid-1970s

that the field of diagnostic radiology underwent a rapid evolution with the advent of chest CT scans.

CT scans allowed cross-sectional imaging and improved visualization of abnormalities as compared with CXRs by enhancing "contrast" and by eliminating superimposition of structures as a result of tomographic sectioning, now in virtually any plane. CT scans permitted better visualization of the airways, mediastinum, and pulmonary vasculature.² CT scans became widely used in day-to-day practice, sometimes to the exclusion of CXR. Consequently, the art of reading CXRs, which had been refined over the years, and whose importance has been ingrained in the minds of radiologists, pulmonologists, and thoracic surgeons, is likely dwindling rapidly.

On the other hand, it is important to point out that the CXR still remains the most commonly ordered screening test, providing a window into the patient's thorax.³ The reasons for this include the ease with which a CXR can be performed (including bedside studies), familiarity of radiologists and some pulmonologists in its interpretation, lower radiation exposure to the patient,⁴ and lower costs when compared with CT scans.⁵

Manuscript received May 21, 2010; revision accepted October 6, 2011.

Affiliations: From the Division of Pulmonary and Critical Care Medicine (Drs Suhail Raoof and Irugulpati), New York Methodist Hospital, Brooklyn, NY; the Department of Radiology (Dr Feigin), The Johns Hopkins University, Baltimore, MD; the Division of Pulmonary and Critical Care Medicine (Dr Sung), Beth Israel Medical Center, New York, NY; the Department of Radiology (Dr Sabiha Raoof), Jamaica Hospital Medical Center, Jamaica, NY; and the Department of Pulmonary and Critical Care Medicine (Dr Rosenow), Mayo Clinic, Rochester, MN.

Correspondence to: Suhail Raoof, MD, FCCP, Division of Pulmonary and Critical Care Medicine, New York Methodist Hospital, 506 Sixth St, Brooklyn, NY 11215; e-mail: sur9016@nyp.org
© 2012 American College of Chest Physicians. Reproduction of this article is prohibited without written permission from the American College of Chest Physicians (<http://www.chestpubs.org/site/misc/reprints.xhtml>).

DOI: 10.1378/chest.10-1302

In addition, a study from 1981 showed that CXRs enable a diagnosis in 46% of the cases in the appropriate clinical setting.⁶ It can be inferred that a significant percentage of these patients, such as those with left ventricular failure, pneumonia, pleural effusion, or rib fracture may not need a follow-up CT scan for diagnosis or further elaboration of the abnormality. The potential long-term adverse effects of the radiation from CT scans will not really be known for another decade or so, but many radiologists are concerned.

A patient's workup may stop at a normal CXR. In other cases, a normal CXR may require a more sensitive imaging study, such as a CT scan, when an early interstitial lung disease, for example, is suspected.⁷ In some instances in which a CT scan has been necessary to establish the diagnosis initially, it may be possible to follow the course of the abnormality with a CXR. However, only having a CT scan without a CXR makes it hard to follow up without the baseline CXR for comparison. More often than not, especially in referral centers, the pulmonologist has prior CXRs from outside in his or her possession for comparison. Finally, if an abnormality is picked up on CXR, more light may be shed on the nature of the abnormality by other imaging modalities. An example may be the case of multiple small pulmonary nodules.

The key to success in interpreting plain CXR includes (1) reading hundreds of normal CXRs to know what is normal and, therefore, what is abnormal, (2) following the same systemic approach to reading a CXR, (3) developing a strong foundation in thoracic anatomy, and (4) generating a carefully considered list of differential diagnoses based upon a detailed history and physical examination prior to reading the CXR. The last point is controversial, since many believe that such an approach may lead to a biased or predetermined reading. However, in the spirit of using clinical information to more critically assess the radiographic findings, we recommend this approach. The intention of this article is to present an organized approach to interpreting chest radiographs based on general radiographic principles, emphasizing close clinical correlation. The ways to minimize missed findings and the limitations of CXR are discussed. The radiologist remains, the primary interpreter of the radiologic images.

PRINCIPLES OF READING CXR

The Importance of Dual Readings

There are three reasons for our emphasis on the importance of dual reading of the CXR by the radiologist and the clinician. First, subtle lesions may be missed on the plain CXR either by the clinician or the radiologist. The number may be as high as 19% of

early lung cancers.⁸ Therefore, a dual "backup" and independent reading of the CXR by a radiologist and a clinician may reduce the number of such missed lesions. Quality of care has become the mantra of all medical centers, so a "free second opinion" only makes sense. Second, the clinician has the advantage of knowing the patient's history, physical, and laboratory findings and is able to show the abnormality to the patient ("a picture is worth a thousand words"). Third, the nonradiology physician must gain sufficient experience with interpreting CXRs in order to teach others (especially trainees) this art.

Reading of CXR by the Radiologist

Most clinicians are not as experienced as chest radiologists in interpreting CXRs. A radiologist typically picks up 70% of abnormalities on a chest radiograph in <0.5 s.⁹ The rapid recognition of lesions is based on gestalt detection.¹⁰ Surprisingly, when radiologists were asked to view CXR for >5 s, no improvement in detection rates of true positives was noted.¹¹

It is important to note that even if a systematic approach is used, 10% to 15% of lesions can be missed

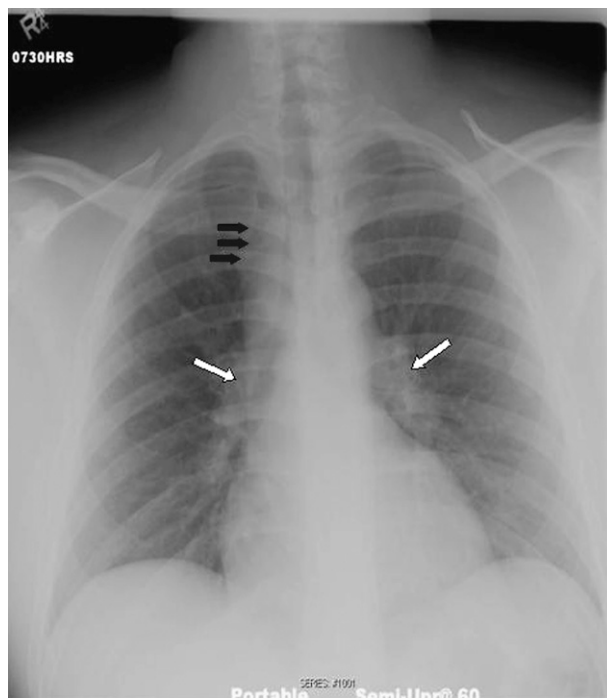


FIGURE 1. Frontal anteroposterior (AP) chest radiograph (CXR) image, showing bilateral hilar adenopathy represented by white arrows and mediastinal adenopathy as shown by transparent arrows. Note that the paratracheal stripe is widened (shown by the black arrows), indicating paratracheal adenopathy. The patient had histoplasmosis; however, the image is indistinguishable from sarcoidosis or even lymphoma. A detailed history elicited from the patient indicated residence in an endemic area for histoplasmosis.

on studies (false negatives), roughly equaling the false-positive rates.¹² There are many factors leading to such errors. They include poor film quality (such as inadequate penetration or rotation) and underlying conditions such as ARDS, which mask the concomitant pneumonia. Reader errors are worsened by fatigue, which can occur after 1 hour of continuous reading.¹³ Finally, “the eye does not see what the mind does not know.” This emphasizes the importance of joint interpretation, first by the clinician and the radiologist and then by the clinician. Failure of the requesting physician to provide relevant clinical information or omission by the radiologist to read the indications of the study can limit diagnostic accuracy.

Reading of CXR by the Nonradiologist

Clinicians and radiologists bring different backgrounds to the interpretation of chest images.¹⁴ Clinicians know the patient’s history and clinical details and often have access to prior studies performed at a different facility, which can be used to compare with new studies. As mentioned earlier, it is best for the clinician and radiologist to communicate closely.

A radiology consultation in the reading room enables the narrowing of differential diagnoses from both the clinical and radiologic perspectives. Moreover, based

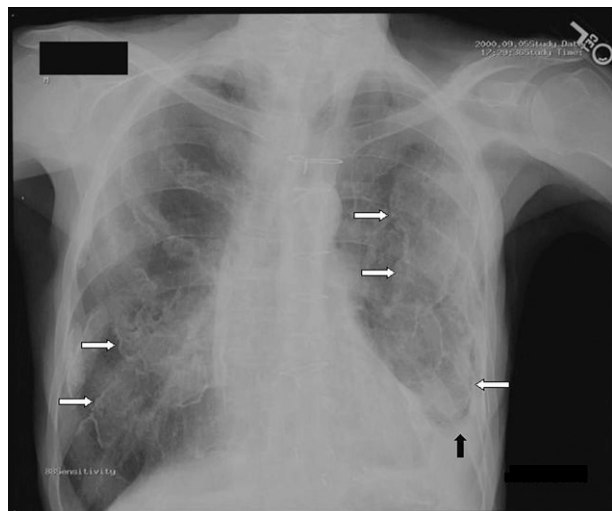


FIGURE 2. Frontal posteroanterior (PA) view of a 64-year-old former asbestos worker. Bilateral pleural plaques with calcifications (white arrows) are visible overlying both lungs and can thus be mistaken for pulmonary abnormalities. En face calcified plaques make the lungs difficult to evaluate for true parenchymal abnormalities, such as asbestosis. There is also a small left pleural effusion (black arrow). Blunting of left costophrenic angle in this case was due to effusion, which could be secondary to malignancy, such as malignant mesothelioma, or residual effusion from previous coronary artery bypass grafting. However, such blunting may also be seen from pleural adhesions and scarring. A decubitus film or CT scan may distinguish these entities.

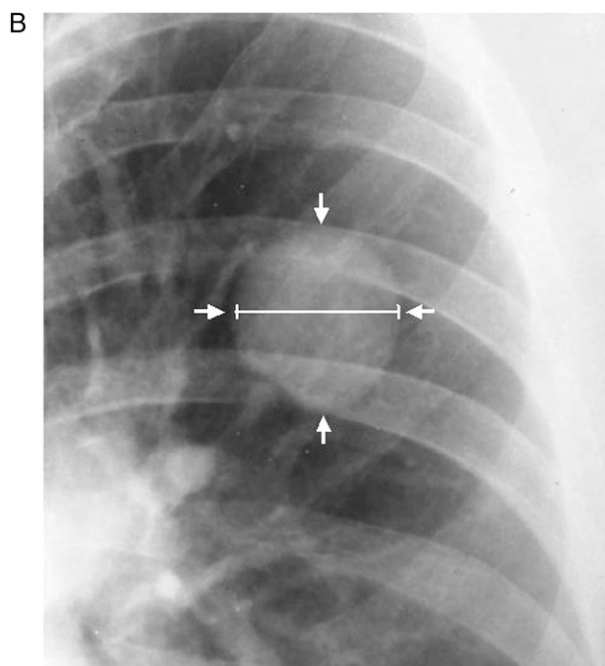
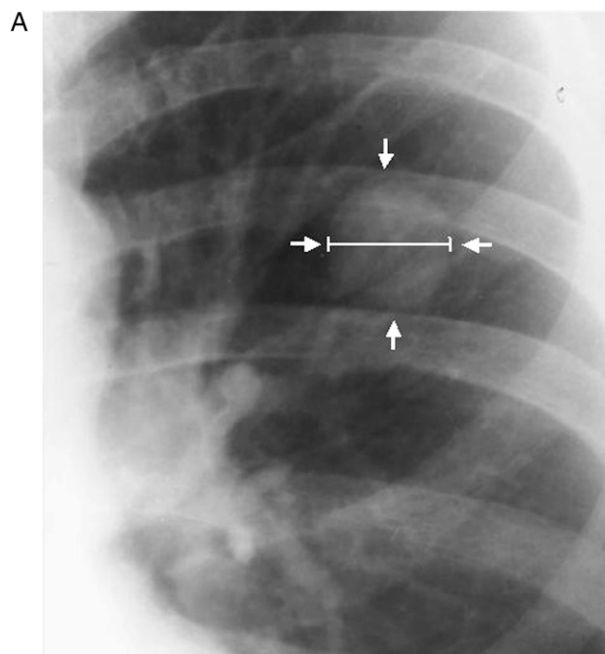


FIGURE 3. A, Close-up view of left upper chest of an 18-year-old man with a well-defined mass 3 cm in diameter as indicated by the arrows. B, Follow-up view taken 2 years later shows the mass now 4.2 cm in diameter, from the original diameter of 3.0 cm (as indicated by the arrows). Since the volume of the sphere is denoted by the equation $\frac{4}{3} \pi r^3$ (where r = radius of curvature), the original volume of this mass has gone from $\frac{4}{3} \pi (1.5)^3$ to $\frac{4}{3} \pi (2.1)^3$. Thus, the volume has increased from 14.13 cm³ to approximately 38.77 cm³. This represents 104% increase in volume of the mass. Of note, the diameter of a nodule has to increase by 26% for the volume to double. In this particular case, the diameter has increased by 40% (from 3.0 to 4.2 cm). The diagnosis was peripheral carcinoid tumor.

on the discussions, the radiologist can often recommend the next appropriate imaging study. All this could save the patient an invasive procedure.

Clinical History and Physical Examination

The clinical history and physical examination should provide the basis for differential diagnoses before the CXR is obtained.¹⁵ Duration and severity of symptoms and signs of infection, risk of lung cancer, or coronary artery disease will help to narrow the differential diagnosis. Social, occupational, and travel history are equally important. For example, a person who lived in an area endemic for histoplasmosis may present with mediastinal and hilar adenopathy (Fig 1). Although the radiographic image may be indistinguishable from that of a patient with sarcoidosis or lymphoma, the geographic residence may give clues to the diagnosis. Also, in retrospect, subtle changes of sarcoidosis and other disease may have been present on previous outside CXRs and missed. Previous exposure to asbestos can explain pleural thickening or calcifications (Fig 2). The presence of a third heart sound (S3 gallop), even in the absence of cardiomegaly, may suggest the possibility of congestive heart failure as the explanation for the findings on the CXR.

Importance of Prior Films

The value of prior studies cannot be overemphasized. An unchanged opacity seen on a CXR 6 months earlier points away from an infective process or malignant neoplasm. A solitary pulmonary nodule on a CXR can be compared with a prior film, especially if the abnormality was missed, to evaluate for stability in its size over time. An enlarging nodule doubles in volume when its diameter increases by approximately 26%.¹⁶ Figure 3 shows two CXRs, 2 years apart, with a lesion that has more than doubled in volume, and the potentially malignant mass (carcinoid) was missed on the first CXR.

How to Self-Learn to Read a CXR

By reading large number of studies, one can appreciate normal structures and their variations as well as abnormal structures. One needs to independently read hundreds of CXRs to develop the confidence to call a film “normal.” For the first approximately

arrows). If the search for lesions is abandoned at the first abnormality noted, a subtle right lower lobe nodule seen in right paracardiac area (short white arrows) (primary bronchogenic carcinoma) will be missed. B, Lateral view shows a mass overlying the lower thoracic spine (white arrow), not clearly visible on the frontal view. C, Single view of chest CT scan shows nodule in posterior right lower lobe (arrow). See Figure 2 legend for expansion of abbreviation

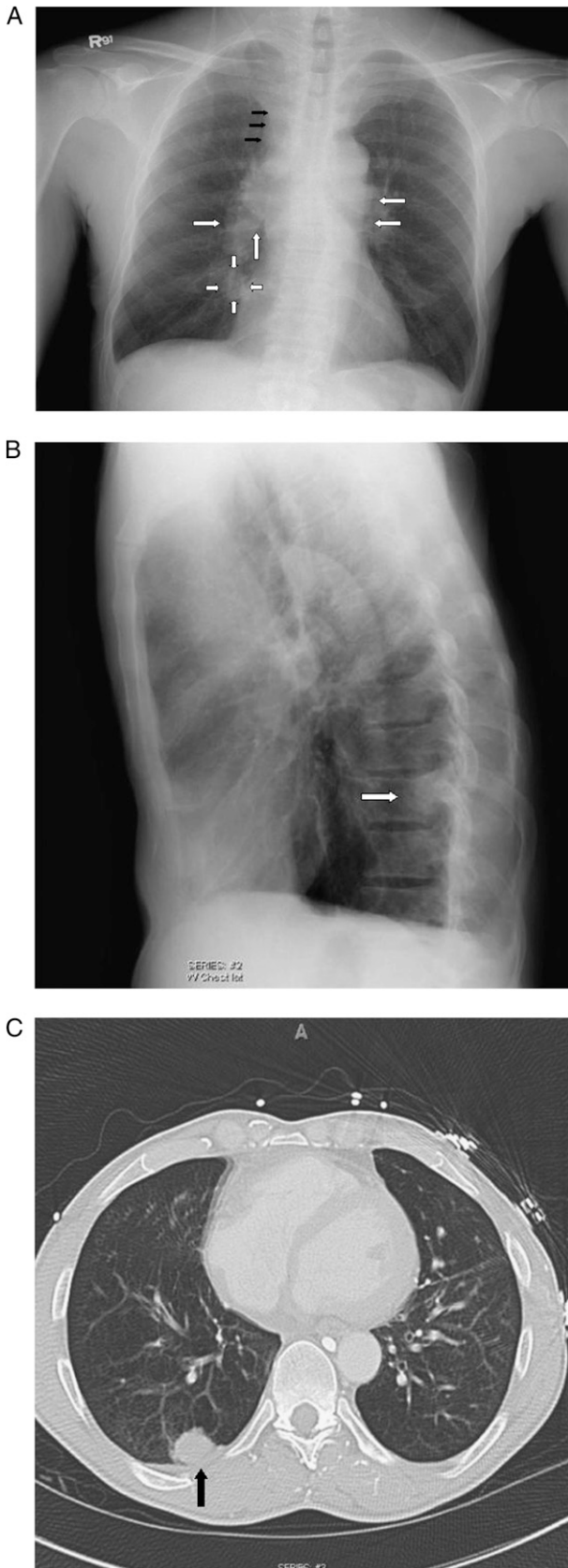


FIGURE 4. A, Frontal PA view of a 52-year-old man with a heavy smoking history showing diffuse bilateral hilar adenopathy (long white arrows) and mediastinal lymphadenopathy (small black

Table 1—Chest Film Search Pattern

Preliminaries

Verify patient information and date on both films and position of LEFT or RIGHT marker on frontal.
Note adequacy of penetration and any technical defects.
Look briefly at the entirety of both films, the PA and the lateral CXRs, for obvious abnormalities. Do not stop with the first abnormality seen.

Frontal

Study the lungs, both up and down and side to side. Include lung volumes, symmetry of markings, and extra opacities.
Check periphery of lungs for pneumothorax and the costophrenic angles for small effusions.
Evaluate mediastinal and cardiac contours, edges, and shape.
Follow trachea to carina and main bronchi.
Look at both hila for enlargement and abnormal bulges.
Trace periphery of the chest: neck, chest wall, bones, diaphragms; check the upper abdomen for free air and bowel gases.

Lateral

Judge the size and shape of the lungs and diaphragms.
Follow the airway from neck to hilum. Note shape of pulmonary arteries.
Note back of heart and darkening toward diaphragm.
Look upward for darkening of anterior mediastinum to the neck.
Follow the spine downward for vertebral bodies and darkening.
Trace periphery: forward through abdomen, up anterior chest wall, and down posterior ribs to the costophrenic angles.

CXR = chest radiograph; PA = posteroanterior.

100 readings, it is a good idea to review the CXR with the radiologist. This practice is a useful learning experience and helps to build confidence in the clinician's mind. The clinician should avoid reading the radiologist's report prior to seeing the actual study, because that may bias the clinician, increasing the chances of a potentially false-negative reading. Another practice to avoid is to make a diagnosis during the interpretation of a study. It is important to objectively describe the findings first. When the reading is complete, a more focused differential diagnosis should be made, taking the history and physical examination into consideration. Constant use of a systematic approach to image interpretation is strongly advocated. There are no absolute rules that dictate which approach to follow, as long as the same approach is followed consistently. Such an approach prevents the reader from getting focused on the most obvious first abnormality seen and omitting other more subtle findings.

Figure 4 shows a prominent right hilar adenopathy with a more subtle nodule in the right lower lobe. If the reader gets focused on the most prominent abnormality, the right lower lobe nodule may be missed. The nodule is seen clearly on a CT image. Search patterns also save time that might be wasted as attention darts from one part of the image to another. Finally, the reader should first begin with differential rather than single pathological diagnosis.

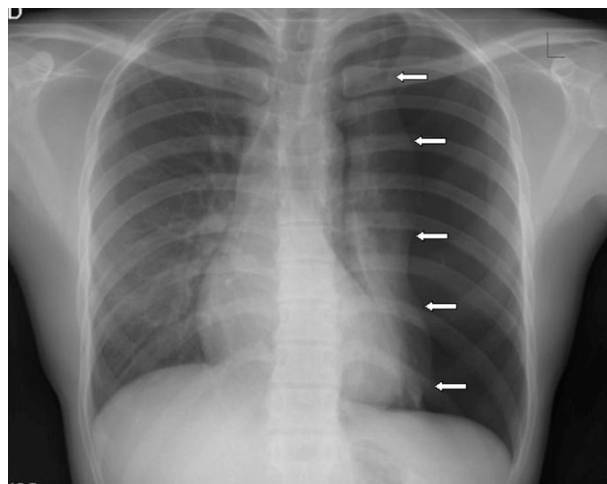


FIGURE 5. Frontal PA view with an obvious pneumothorax on the left side and absent lung markings indicated by arrows. The opacity adjacent to the heart border represents the collapsed lung. Air has tracked between the collapsed lung and the aorta. Note the subtle depression of the left hemidiaphragm and the slight shift of the mediastinum to the right. See Figure 2 legend for expansion of abbreviation.

Systematic Search of the CXR

The initial imperative in effective use of the CXR is the detection of all the findings on the available images, including the lateral view. This is best accomplished by adoption of a thorough search pattern that

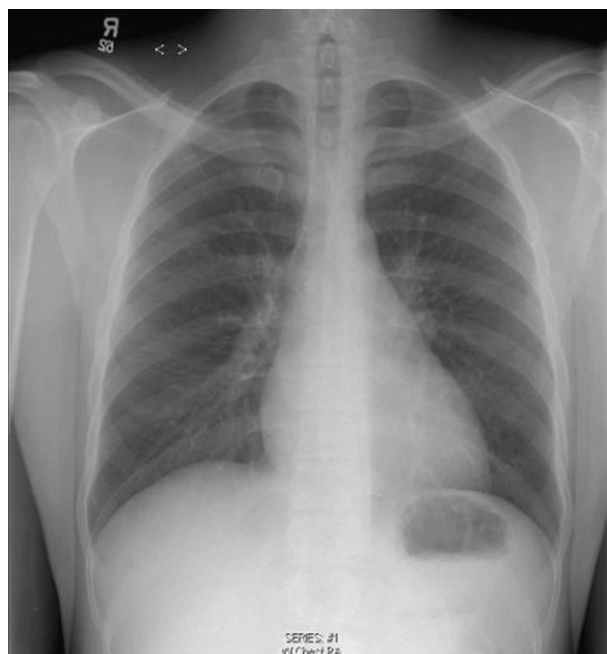


FIGURE 6. Normal PA frontal image performed in inspiration shows a well-penetrated radiograph. Vertebrae are visible behind the heart. Left hemidiaphragm is visible to the edge of the spine. The lungs are appropriately visualized and the vascular markings are not prominent. See Figure 2 legend for expansion of abbreviation.

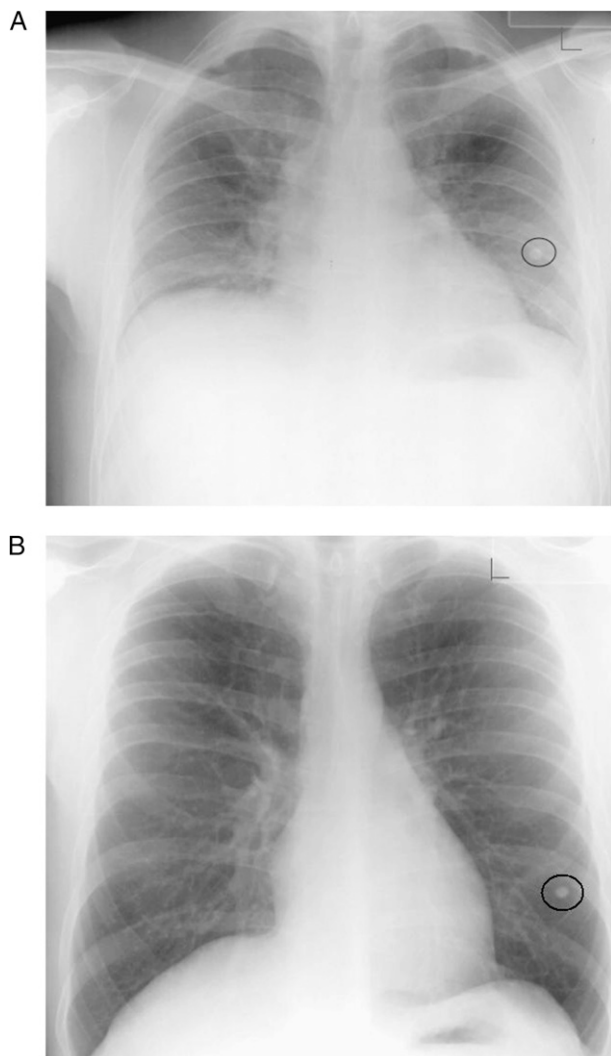


FIGURE 7. A, The frontal PA image performed in exhalation. The CXR shows what appear to be increased vascular markings, suggestive of left-sided heart failure. The hila appear to be prominent as well, further corroborating the diagnosis of pulmonary edema. B, The same patient's CXR after deeper inspiration, performed almost immediately after the prior film. The vascular markings are not prominent. The hila appear to be normal. On both images, a nodule with circle around it is seen in the left midlung zone, a subtle finding that may be missed if the reader does not follow a systematic approach to interpreting plain chest radiographs. See Figure 1 and 2 legends for expansion of abbreviations.

includes all the useful features and emphasizes the areas of greatest importance in clinical practice.¹⁷

The conventional teaching has been to conduct the search of the frontal view by studying the periphery of the image, including the bones, neck, and upper abdomen. The theory behind this was the belief that we would forget to complete our search of these areas of the image once we found abnormalities in the lungs or mediastinum. The major problem with this approach is that the most important abnormalities that impact patient care are found in the lung parenchyma and mediastinum; analysis of the periphery

can provide very useful ancillary information that helps us understand these principal findings. Therefore, many radiologists and clinicians automatically look at the lungs first. The essential elements of the complete search are summarized in Table 1. It is far more important to include every element in the list than it is to adopt this specific order.

Preliminaries:

1. Verify that the study you are reading is correctly labeled with regard to the patient's name or number or both, the date and time, and the position of the right or left sides of the patient (for the frontal view). Serious errors can be committed by correct interpretations of the wrong patient or by viewing an old image. Never use the shape or position of the heart to judge left and right for the frontal image; abnormalities of

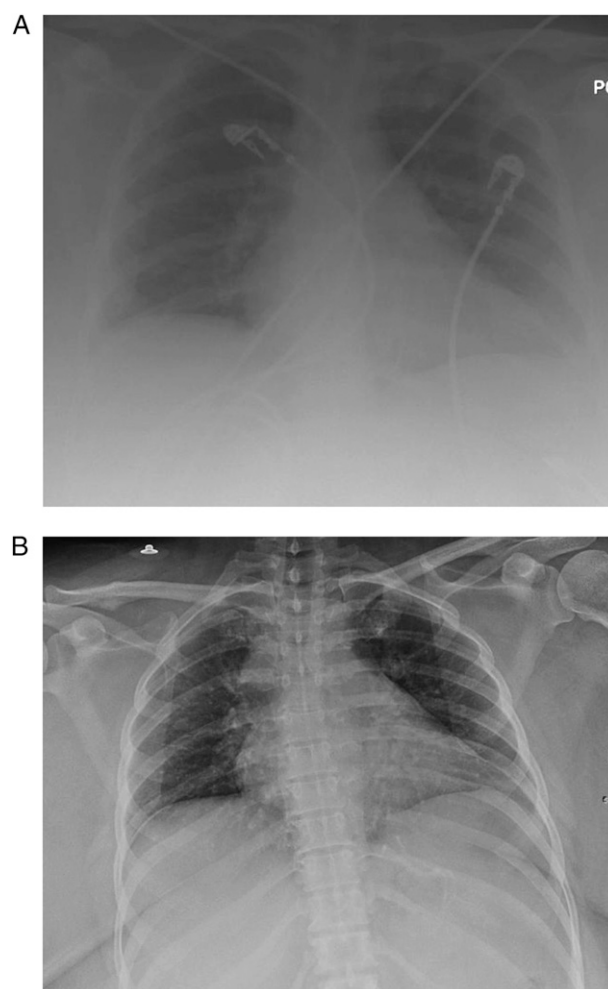


FIGURE 8. A, An underpenetrated radiograph obtained from a patient. Vertebral bodies are not clearly visualized. Retrocardiac area is not optimally visualized. B, A well-penetrated radiograph in the same patient. Vertebrae are visible behind the heart. Left hemidiaphragm is visible to the edge of the spine.

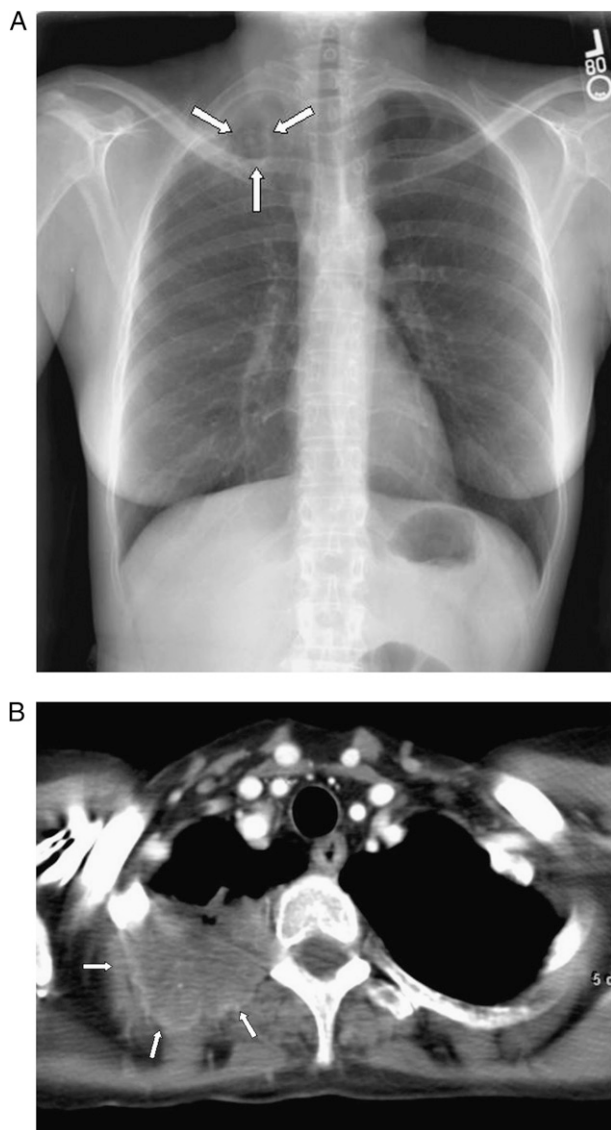


FIGURE 9. A, The frontal image depicts a hazy opacity in the right apex, above the anterior aspect of the right clavicle as delineated by the arrows. The second and third ribs are not clearly visualized posteriorly. This patient had a Pancoast tumor in the right lung. B, Single view of chest CT scan shows Pancoast tumor in the right apex as indicated by arrows.

the degree of inflation of the lungs can cause the cardiac apex to shift. Tension pneumothorax displaces the mediastinum, especially the heart, toward the contralateral side. Figure 5 shows a left-sided pneumothorax causing slight shift of heart to the right.

2. Look for serious technical defects and artifacts that can affect interpretation. You should be able to see lung markings and ribs through the heart if the study is performed correctly. Figure 6 shows a good-quality film with adequate penetration and deep inspiration. Figure 7A shows a film performed in exhalation in a separate

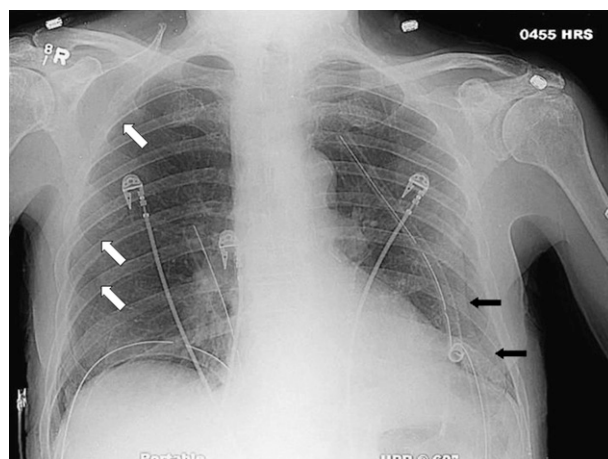


FIGURE 10. Frontal AP view of a 60-year-old trauma patient with bilateral chest tubes. There is a small right pneumothorax, best seen lateral to the right upper lung as a thin line with no lung markings farther lateral indicated by white arrow. There is also a prominent skin fold on the left, visible lateral to the left chest tube as indicated by black arrows. Note the gradual increase in opacity that stops abruptly at an edge just medial to the left lateral ribs, typical of skin fold. In many instances, the skin fold will extend beyond the hemithorax or end abruptly, without allowing the margin to be traced to the chest wall. See Figure 1 legend for expansion of abbreviation.

patient. It should be pointed out that during poor inspiration (Fig 7A), the lung fields could very easily be interpreted as showing pulmonary vascular congestion. An image obtained during deeper inspiration (Fig 7B) dispels that

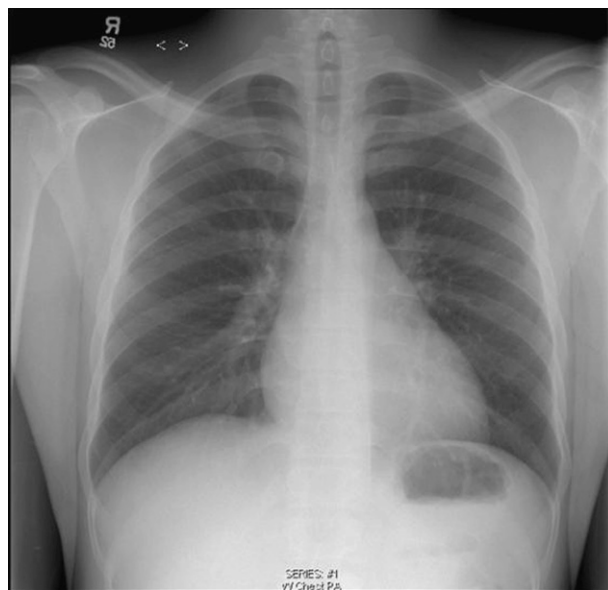


FIGURE 11. Normal frontal PA view showing typical contours of the mediastinum. The edges of the right side of the mediastinum consist of the superior vena cava, the right bronchus, and the right atrium. The bumps (or moguls) on the left side are the aortic knob, the main pulmonary artery, and the left ventricle. See Figure 2 legend for expansion of abbreviation.

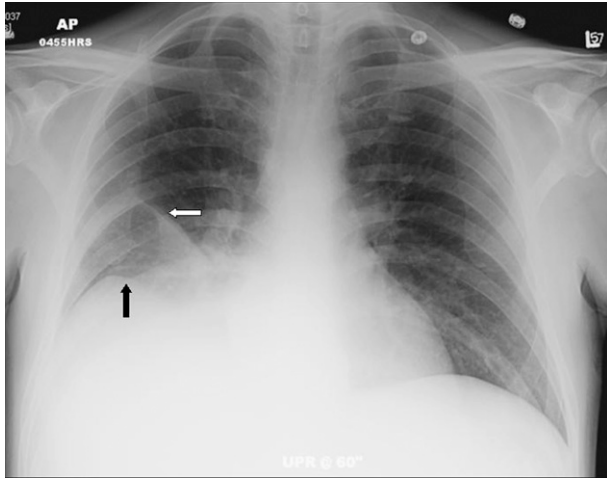


FIGURE 12. A 48-year-old woman with metastatic ovarian carcinoma. Frontal AP view shows right subpulmonic pleural effusion (black arrow) with extension into right major fissure (white arrow). Note the lateral shift of the highest point of opacity beneath the right lung, when compared with the normal curvature of the hemidiaphragm. The right hemidiaphragm appears to be elevated (due to the fluid). See Figure 1 legend for expansion of abbreviation.

impression. Figure 8A shows an underpenetrated film with resultant prominence of all vascular structures. The impression is similar to the prior CXR (Fig 7A) obtained in a poor inspiratory phase. Figure 8B shows better penetration and hence a clear visualization of the parenchymal and hilar structures. If you are viewing the image electronically, you should be able to easily adjust contrast and density to maximize visualization of all structures. With hard copy films, however, serious defects in penetration can obscure major abnormalities, particularly in the lung bases.

3. Gestalt both views to get an overall impression of the images. As one gains more experience with plain chest radiographs, it becomes increasingly frequent to observe that something is abnormal, although the exact nature of the abnormality may require further study.

Frontal

1. Study the lungs, both up and down and side to side. It is critically important to look for asymmetries by comparing opposite sides of every part of both lungs. Be aware that 15% of the lung can be hidden by cardiovascular structures and the diaphragm. The lateral image can be helpful in looking for these obscure lesions on posteroanterior (PA) films. (Figs 4A-4C)
2. It is important to distinguish the two frontal views, PA and anteroposterior (AP). In the PA projection, the patient is facing the screen. In the AP view, the posterior ribs are more clearly defined and the heart is magnified. Normally,

the PA view is preferred since the clavicles are not projected above the apices and the ribs do not appear horizontal.

3. Look for differences in inflation, vessel size and position, and overall degree of whiteness. Note any small opacities that are larger than the diameter of the nearest vessels. Judge the texture of any abnormal lung markings, such as extra lines (as in interstitial patterns) and cloudlike whiteness (such as consolidations). Sometimes it is easy to over-read interstitial markings; an older study can be invaluable for comparison in these instances.
4. Look carefully at the upper third of the lungs, including the apices. Overlying clavicles make interpretation difficult. The majority of parenchymal lung cancers are found in the upper half of the lung fields. It is important to pay attention to both apices of the lungs and look for asymmetry. Figure 9 shows the CXR of a patient who presented with arm pain. Asymmetry at the apices suggests superior sulcus (Pancoast) lesion in the right lung.
5. Check the periphery of both lungs for pneumothorax and pleural opacities that could signify effusions or pleural masses. Most missed

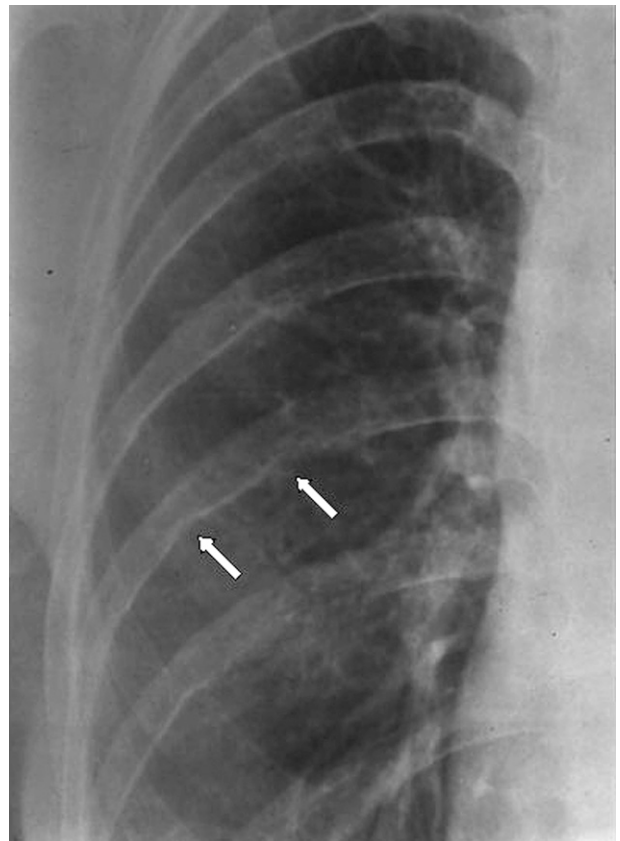


FIGURE 13. Frontal PA CXR showing rib notching. This is best appreciated on the inferior border of the rib posteriorly with arrows pointing. See Figure 1 and 2 legends for expansion of abbreviations.

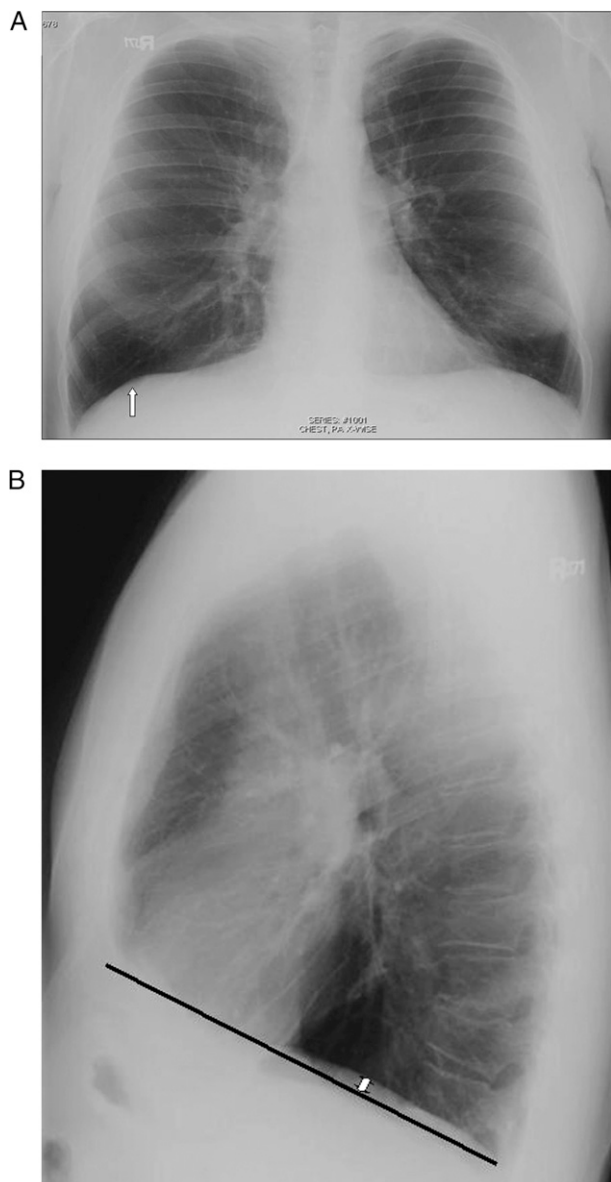


FIGURE 14. A, Frontal PA film showing hyperinflation, especially in the upper lungs, attenuation of lung markings, and flattening of diaphragms with loss of normal curvature (arrow). B, A 44-year-old man with COPD secondary to prolonged smoking. Lateral film shows one criterion for defining flattening of the diaphragms: drawing a line from the posterior to anterior costophrenic angles and measuring the distance from this line to the apex of the diaphragm. If the height of the line is <2.7 cm (as depicted by double-headed arrow), the criterion for flattening is fulfilled.

pneumothoraces are the result of failure to look for them. Figure 10 shows a pneumothorax, which needs to be distinguished from skin crease.

6. Look for pleural thickening or calcification. In cases of pleural effusions, remember that it takes 200 to 400 mL of pleural effusion to blunt the costophrenic angles.
7. Evaluate mediastinal contours and edges. Learn to be comfortable with the normal silhouette of this structure. Hilar configurations are frequently

misinterpreted or abnormalities missed (Fig 11). Look down both sides of the mediastinum and verify that no abnormal bulges are present. Normal bulges on the left side of the mediastinum are, in order from the top, the aortic knob, the main pulmonary artery (at the level of left hilum), and the left ventricle. The only normal bulge on the right side is the right atrium. Additional bulges are usually abnormalities, such as enlarged mediastinal lymph nodes.

8. Follow the trachea to the carina and then the main bronchi into the hila. The central airways may be displaced or compromised by narrowing or endobronchial masses. Displacement of a main bronchus is often a sign of lobar obstructive atelectasis (collapse).
9. Look at both hila for enlargement and abnormal bulges. Pay attention to the right paratracheal area. Subtle lymphadenopathy here may represent the only plain radiographic evidence of sarcoidosis or metastatic diseases. Figure 4 shows right hilar lymph node enlargement.
10. Trace the periphery of the chest and the upper abdomen. Start with the trachea in the neck and look for asymmetry of the soft tissues on the sides, then look at the position and shape of the diaphragms and at the upper abdomen for abnormal air. Normally, the right diaphragm is higher than the left. However, a subpulmonic effusion can appear similar to elevated hemidiaphragm,

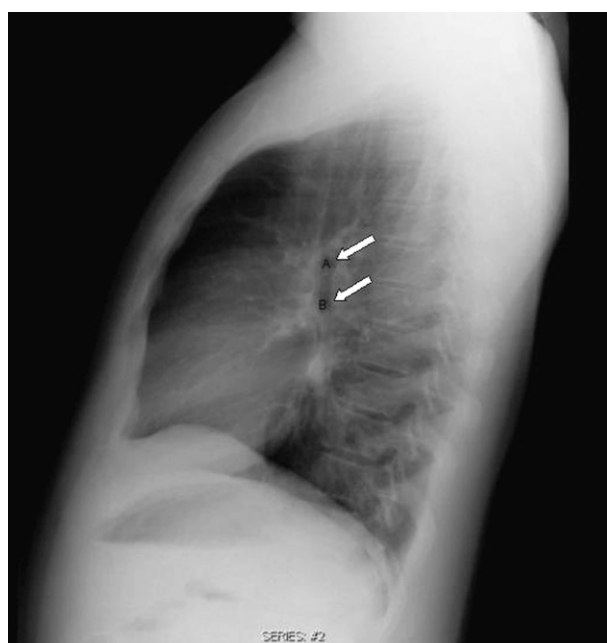


FIGURE 15. Normal lateral view. A, Lucencies of right upper lobe bronchus are indicated. B, Lucencies of left main bronchus are indicated. The right pulmonary artery is the opacity anterior to the bronchi and the left pulmonary artery is the opacity posterior to them.

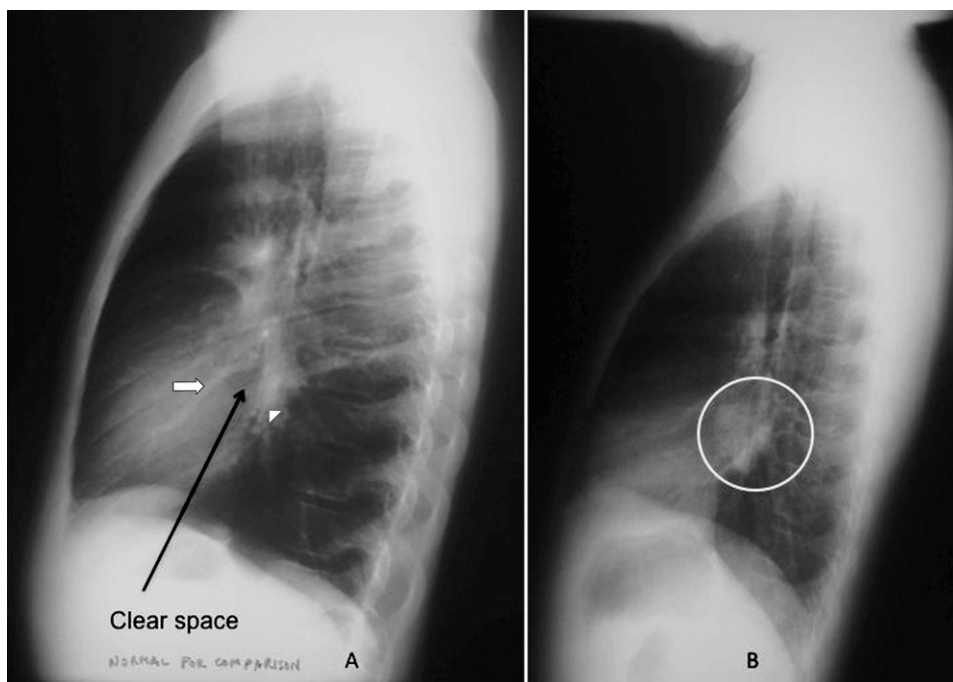


FIGURE 16. A, The lateral film shows descending pulmonary veins in the 6 o'clock position indicated by the arrowhead and the middle lobe vessels in the 8 o'clock position indicated by the white arrow. The 7 o'clock position is normally described as the clear space (indicated by long black arrow). B, The same patient, 1 year later, when he was diagnosed with sarcoidosis. The clear 7 o'clock position enclosed within the circle is occupied by lymph nodes.

sometimes without blunting of the costophrenic angles. Figure 12 shows subpulmonic effusion.

11. Follow the ribs, especially at their turning points laterally. Check the inferior margin of the ribs

for notching that may be consistent with coarctation of aorta. Figure 13 shows rib notching.

Lateral

1. Judge the size and shape of the lungs and the position and shape of the diaphragms. The overall size of the lungs on the lateral view is the best mirror of total lung volume. Degree of flattening of the diaphragms (generally defined as a height of < 2.7 cm measured from anterior to posterior costophrenic angles)¹⁸⁻²⁰ is also much easier to determine on the lateral view than on the frontal (Fig 14A). Progressive flattening generally reflects presence of emphysema but can be seen with acute severe asthma. Figure 14A and 14B frontal PA with lateral CXR shows flattening of the diaphragm.
2. Follow the airway from neck to the hilum, where the pulmonary arteries can be evaluated. Any tracheal deviation should be noted, and there should be relative lucency behind the tracheal air column. The center of the hilar structures is the left main bronchus, seen on end as a rounded lucency in direct line with the trachea. The cylindrical opacity anterior to the left bronchus is the right pulmonary artery. The curved opacity posterior to that bronchus is the left pulmonary

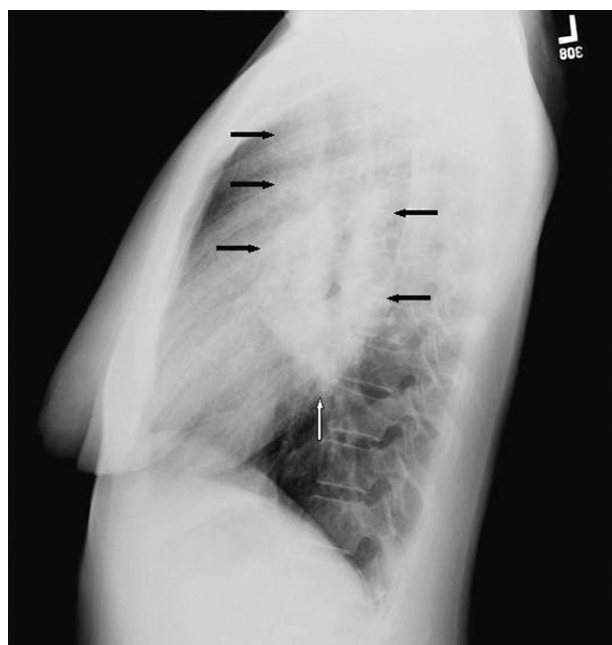


FIGURE 17. Extensive right and left hilar lymphadenopathy (black arrows) and subcarinal lymphadenopathy (white arrow) visible on the lateral film.

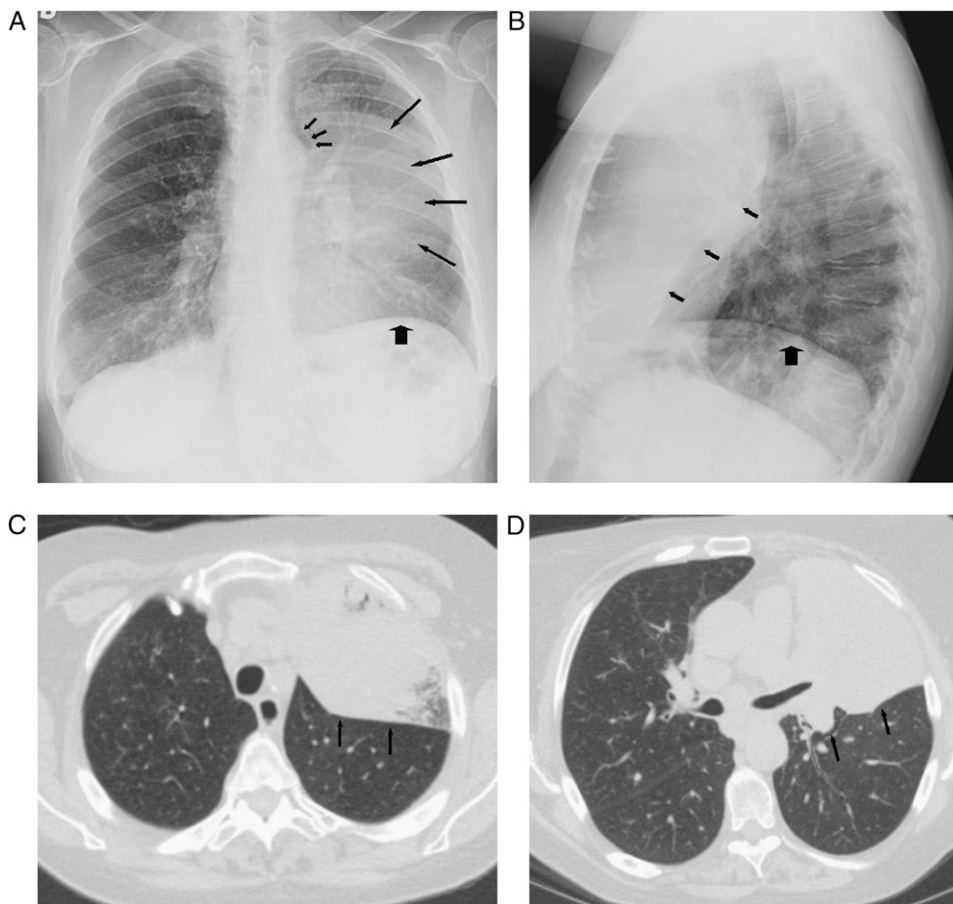


FIGURE 18. A, A 37-year-old man with carcinoid tumor in left upper lobe (LUL) bronchus and complete LUL atelectasis. The Frontal PA image shows an opacity in the left lung (long arrows) and left lung volume loss. There is loss of normal cardiac silhouette and elevation of left hemidiaphragm (thick arrow). The lucency lateral to the aortic arch is called the Luftsichel (air crescent) sign as depicted by small arrows. B, The lateral view shows the left major fissure as an edge (thin arrows) displaced upward and forward to lie above the heart and elevated left hemidiaphragm (thick arrow). C and D, CT scan obtained from the same patient showing collapsed left upper lobe. The arrows are pointing to the fissure separating the left upper lobe and the lower lobe. See Figure 2 legend for expansion of abbreviation. (Figure provided courtesy of Rakesh Shah, MD, North Shore University Hospital.)

artery, which enters the left lung by passing over that bronchus and descending behind it. These structures are depicted in Figure 15. Hilar lymphadenopathy is often quite obvious on the lateral view as extra lobulations just inferior to the pulmonary arteries. Subcarinal adenopathy is noted as a filling of the 7 o'clock position on the lateral film (Figs 16A, 16B, 17 [vertical white arrow]).

3. Look for darkening as you look upward from the widest part of the heart toward the trachea. Again, there should be no edges of large opacities in this region. The top of the heart is never visible as an edge, because the aorta and pulmonary artery emerge from it. Any horizontal or oblique edge above the heart generally reflects the presence of an enlarged vessel, a mass in lungs or mediastinum, or other abnormalities such as

collapse of an upper lobe—the Luftsichel sign. (Figs 18A–18D).

4. Follow the spine downward, looking at the shape of each vertebral body and also looking for gradual darkening from the midthoracic vertebrae to the diaphragms due to overlying muscle. Excess lightening of the image in the region of the lower thoracic vertebrae generally is caused by masses or consolidative patterns in the lower lobes, collapse of those lobes (Fig 19), or a posterior mediastinal mass. Approximately 10% of neurogenic tumors demonstrate an associated intraspinal component; CT scan of the spine and/or MRI are required to further evaluate.²¹
5. Trace around the periphery of the image. Find the bowel gases in the upper abdomen and check for pneumoperitoneum, and then pass over the

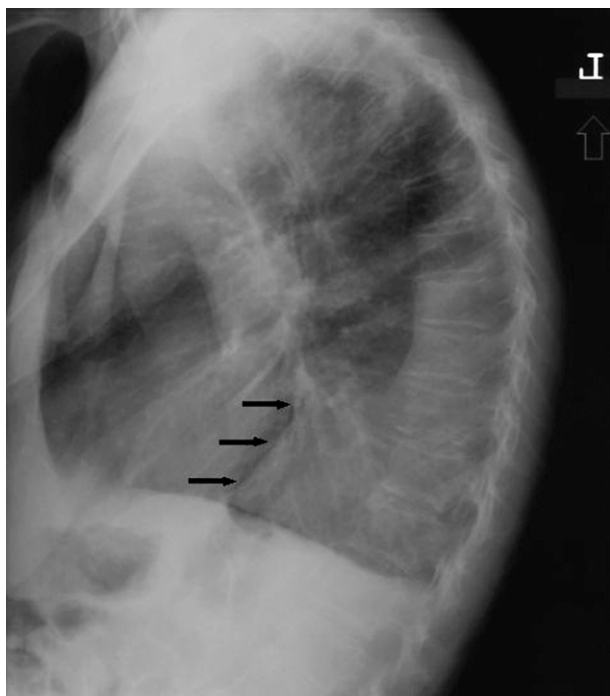


FIGURE 19. Lateral view of 63-year-old man with a history of COPD who now has a carcinoma obstructing his left lower lobe bronchus. Increased opacity is visible behind the heart and overlying the lower thoracic spine, and the left hemidiaphragm is concealed. Normally, as we work our way inferiorly, the spine gets darker. Absence of this darkening, as exemplified by this lateral film (arrows pointing), signifies abnormality in the lower lobes, lower mediastinum, or inferior portion of the pleural space.

sternum and anterior chest wall to the neck. Last, look downward behind the vertebral bodies, judging the posterior turning points of the ribs and ending at the costophrenic angles to find pleural effusions.

Limitations of Plain Chest Radiographs

CXR is usually a screening test. The major limitations of CXR include:

1. Limits of resolution: A lesion < 0.8 to 1.0 cm is not usually visualized, especially if it is not calcified.²² By the same token, characteristics of diffuse lung disease or multiple small nodules will be less well characterized on the CXR as compared with high-resolution CT scan.
2. Inability to visualize vascular structures: Vascular anomalies can be often confused with mediastinal masses, such as a tortuous aortic knob.²³ CT scans with contrast are able to visualize vascular structures that are not visualized on plain CXR (Figs 20A, 20B).
3. Visualization of three-dimensional structures on a two-dimensional plane: This results in significant overlap of shadows, resulting in missed abnormalities (Figs 21A, 21B).

There have been remarkable advances in the quality of digital chest images since a letter appeared in this journal by Bennett E. Ojserkis²⁴ that questioned the diagnostic quality of plain film chest images obtained using digital equipment. The present status of plain chest imaging is that digital images have become the norm in many radiology departments, especially in the United States and Europe. The resolution of the images is now equal to or greater than the resolution of hard-copy plain films. An enormous advantage of digital imaging is the ability to manipulate the technique of the image, most importantly the contrast and density. The substantial cost of establishing digital imaging is generally more than justified by the

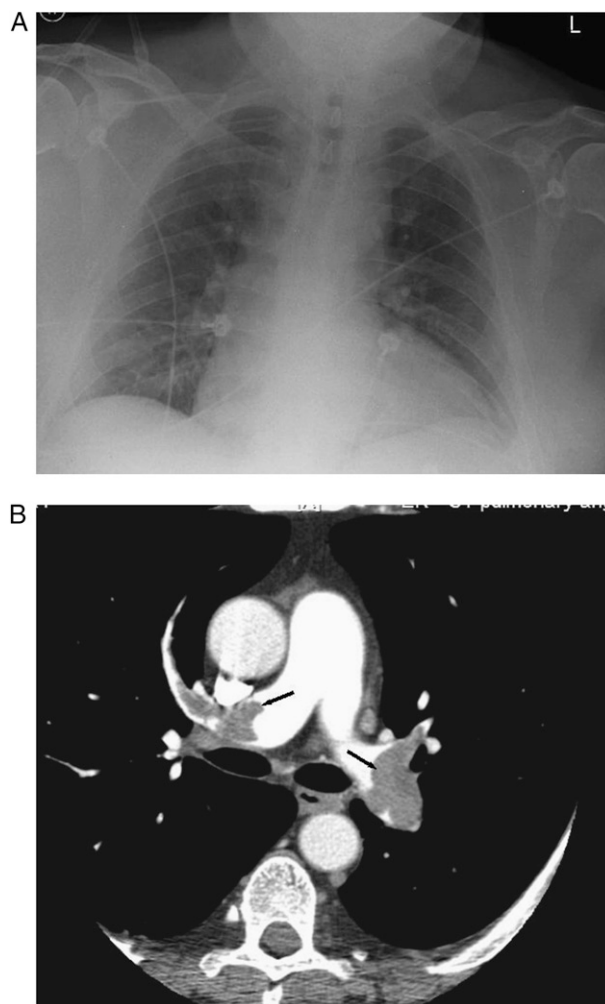


FIGURE 20. A, Plain AP CXR showing a rotated film. The heart appears to be large. The pulmonary arteries appear normal. B, Chest CT scan of the same patient showing large filling defects in both main pulmonary arteries (arrows). Contrast enhancement of the pulmonary arteries allows visualization of pulmonary emboli, which are always missed on plain CXR. See Figure 1 legend for expansion of abbreviations.

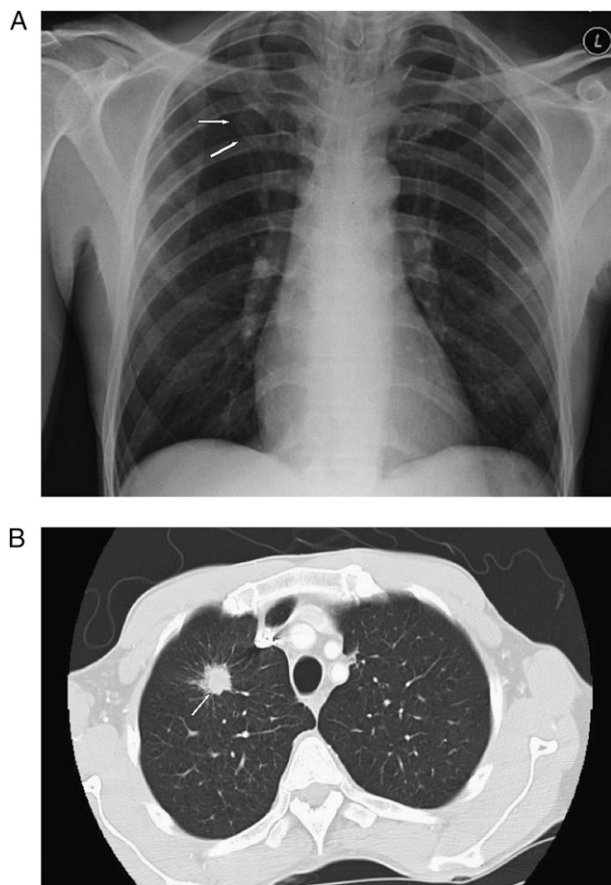


FIGURE 21. A, Frontal PA image of plain CXR, showing a barely visible right-sided hazy opacity just below the first rib anteriorly and medially with the arrows pointing toward the opacity. B, Chest CT scan of the same patient showing a spiculated mass as shown by the arrows, highly suspicious for malignancy. Bony structures at the apices may mask small lesions on the plain CXR. See Figure 1 and 2 legends for expansion of abbreviations.

savings in the cost of hard-copy film and the cost of storing hard images. Digital imaging has also revolutionized the ability to send images electronically or on discs to anyone who needs them. There are no longer any serious drawbacks to their use and there are no longer any advantages to maintaining hard-copy plain chest imaging for optimal patient care.

SUMMARY

Understanding the properties of plain chest radiography, including its advantages and pitfalls, is important to successful interpretation. Skills in interpreting CXR must be maintained, since every pulmonary patient does not need a CT scan of the chest. Pursuing a systematic search for lesions on the CXR will minimize missed lesions. The most difficult film to read is a normal CXR. Confidence in calling a CXR as normal comes from the accrued experience gained after reading hundreds of CXRs. Under the appro-

prate clinical scenarios, many entities can be ruled out on a CXR, thus guiding the clinician to developing a systematic diagnostic algorithm. The readers are reminded that incorporating detailed clinical information with the request, or personal communications with the radiologist regarding the differential diagnosis, can often resolve an otherwise difficult clinical predicament. If you do see something that was missed by the radiologist, call for prior CXRs if you do not already have them, then go to the radiologist who read the image and discuss it with him or her.

ACKNOWLEDGMENTS

Financial/nonfinancial disclosures: The authors have reported to *CHEST* the following conflicts of interest: Dr Sung was the principal investigator for Broncus Technologies 2007 to 2009. Drs Suhail Raoof, Feigin, Sabiha Raoof, Irugupati, and Rosenow have reported that no potential conflicts of interest exist with any companies/organizations whose products or services may be discussed in this article.

REFERENCES

1. Kevles Holzmann B. *Naked to the Bone: Medical Imaging in the Twentieth Century*. Camden, NJ: Rutgers University Press; 1997:19-22.
2. Naidich DP, Webb WR, Müller N, et al. *Computed Tomography and Magnetic Resonance of the Thorax*. 4th ed. Philadelphia, PA: Lippincott Williams & Wilkins; 2007:512-29.
3. Gurney JW. Why chest radiography became routine. *Radiology*. 1995;195(1):245-246.
4. Simpson G, Hartrick GS. Use of thoracic computed tomography by general practitioners. *Med J Aust*. 2007;187(1):43-46.
5. Tigges S, Roberts DL, Vydareny KH, Schulman DA. Routine chest radiography in a primary care setting. *Radiology*. 2004;233(2):575-578.
6. Fink DJ, Fang M, Wyle FA. Routine chest x-ray films in a Veterans Hospital. *JAMA*. 1981;245(10):1056-1057.
7. Hunninghake GW, Lynch DA, Galvin JR, et al. Radiologic findings are strongly associated with a pathologic diagnosis of usual interstitial pneumonia. *Chest*. 2003;124(4):1215-1223.
8. Quekel LG, Kessels AG, Goei R, van Engelsloven JM. Miss rate of lung cancer on the chest radiograph in clinical practice. *Chest*. 1999;115(3):720-724.
9. Tuddenham WJ. Visual search, image organization, and reader error in roentgen diagnosis. Studies of the psychophysiology of roentgen image perception. *Radiology*. 1962;78:694-704.
10. Oestmann JW, Greene R, Bourgouin PM, Linetsky L, Llewellyn HJ. Chest "gestalt" and detectability of lung lesions. *Eur J Radiol*. 1993;16(2):154-157.
11. Christensen EE, Murry RC, Holland K, Reynolds J, Landay MJ, Moore JG. The effect of search time on perception. *Radiology*. 1981;138(2):361-365.
12. Renwick IG, Butt WP, Steele B. How well can radiographers triage x ray films in accident and emergency departments? *BMJ*. 1991;302(6776):568-569.
13. Vertinsky T, Forster B. Prevalence of eye strain among radiologists: influence of viewing variables on symptoms. *AJR Am J Roentgenol*. 2005;184(2):681-686.
14. Halvorsen JG, Kunian A. Radiology in family practice: a prospective study of 14 community practices. *Fam Med*. 1990;22(2):112-117.

15. Loy CT, Irwig L. Accuracy of diagnostic tests read with and without clinical information: a systematic review. *JAMA*. 2004; 292(13):1602-1609.
16. Ost D, Fein AM, Feinsilver SH. Clinical practice. The solitary pulmonary nodule. *N Engl J Med*. 2003;348(25):2535-2542.
17. Carmody DP, Kundel HL, Toto LC. Comparison scans while reading chest images. Taught, but not practiced. *Invest Radiol*. 1984;19(5):462-466.
18. Webb RW, Muller NL, Naidich DP. *High Resolution CT of the Lung*. 3rd. Philadelphia, PA: Lippincott Williams and Wilkins; 2001:436-437.
19. Burki NK. Conventional chest films can identify airflow obstruction [editorial]. *Chest*. 1988;93(4):675-676.
20. Burki NK. Roentgenologic diagnosis of emphysema. Accurate or not? *Chest*. 1989;95(6):1178-1179.
21. Strollo DC, Rosado-de-Christenson ML, Jett JR. Primary mediastinal tumors: part II. Tumors of the middle and posterior mediastinum. *Chest*. 1997;112(5):1344-1357.
22. Huston J III, Muhm JR. Solitary pulmonary opacities: plain tomography. *Radiology*. 1987;163(2):481-485.
23. Bhalla S, Caceres J. Plain-film and CT evaluation of the adult mediastinum and hilum: pitfalls vs. disease. In: Hodler J, von Schulthess GK, Zollikofer CL, eds. *Diseases of the Heart, Chest & Breast*. Milan, Italy: Springer; 2007:19-24.
24. Ojserkis BE. Are digital chest x-rays good enough? *Chest*. 1998;113(1):256.

Interpretation of Plain Chest Roentgenogram

Suhail Raoof, David Feigin, Arthur Sung, Sabiha Raoof, Lavanya Irugulpati
and Edward C. Rosenow III

Chest 2012;141; 545-558
DOI 10.1378/chest.10-1302

This information is current as of March 6, 2012

Updated Information & Services

Updated Information and services can be found at:

<http://chestjournal.chestpubs.org/content/141/2/545.full.html>

References

This article cites 20 articles, 15 of which can be accessed free at:

<http://chestjournal.chestpubs.org/content/141/2/545.full.html#ref-list-1>

Permissions & Licensing

Information about reproducing this article in parts (figures, tables) or in its entirety can be found online at:

<http://www.chestpubs.org/site/misc/reprints.xhtml>

Reprints

Information about ordering reprints can be found online:

<http://www.chestpubs.org/site/misc/reprints.xhtml>

Citation Alerts

Receive free e-mail alerts when new articles cite this article. To sign up, select the "Services" link to the right of the online article.

Images in PowerPoint format

Figures that appear in *CHEST* articles can be downloaded for teaching purposes in PowerPoint slide format. See any online figure for directions.

